

# Vet Topics

SPRING 2024

## To catch a cat killer

By Dorsa Mehrabanpour


 Caitlin Taylor

Feline infectious peritonitis (FIP) is one of the most common infectious diseases in cats globally, and without expensive medication, the illness is virtually 100 per cent fatal in feline patients.

I'm part of a University of Saskatchewan (USask) research team whose members are aspiring to use an advanced medical imaging technique — positron emission tomography scan (PET-CT) — to develop a more rapid, non-invasive way to diagnose and monitor response to anti-viral therapy for this deadly disease in cats.

If our research work is successful, it could mark a major advancement and provide a non-invasive imaging tool for FIP diagnosis.

Feline coronavirus (FCoV), the virus that causes FIP, belongs to the same family

as the coronavirus that causes COVID-19 in people. FCoV has two biotypes: a very common, avirulent form referred to as feline enteric coronavirus (FECV), and a virulent form that causes FIP.

FECV is very common in cats, and if an affected cat shows any clinical signs, it's usually mild diarrhea. This form of the virus is shed in the cat's feces, allowing other cats to be infected. In an infected cat, FECV can mutate into the virulent FIP virus — allowing systemic spread within the cat's body. Contributing factors to FIP's development include stress, age and genetics that help determine the type of immune response the cat has to the virus.

For cats with FIP, the disease can present in a few different forms referred to as dry, wet or a combination of both

over time, as well as more localized forms including neurologic and ocular subtypes.

Veterinarians can make a presumptive diagnosis of FIP, but the only way to definitively diagnose it is through immunohistochemistry — the “gold standard” for diagnosing FIP. This lab test is most commonly performed on tissue collected from an invasive surgical biopsy. Unfortunately, the surgery may potentially cause the disease to worsen or even lead to the patient's death.

Treating the disease is another challenge. The medication, GS-441524, has shown an efficacy rate of over 80 per cent, but until recently, it was only available through the black market online. The expensive medication's availability changed in February 2024 when Canadian

*Continued on next page.*

# TO CATCH A CAT KILLER *continued*

veterinarians gained legal access to anti-viral drugs that can treat FIP.

Our team consists of Dr. Liz Snead, my graduate supervisor and a small animal internal medicine specialist, and my co-supervisor, Dr. Jaswant Singh, who brings expertise in histology and imaging. In addition to these two Western College of Veterinary Medicine (WCVN) researchers, other members are Dr. Eric Price, Canada Research Chair in Radiochemistry and an assistant professor of chemistry in the USask College of Arts and Science, and Matthew Hutchison, a nuclear medicine technician at the university.

Our research goal is to develop a specific probe to allow for the defin-

itive diagnosis of FIP using PET-CT imaging. In addition to developing the first non-invasive imaging diagnostic technique for FIP, our research team's work could also potentially pave the way for developing an alternative or adjunct treatment for FIP using radioimmunotherapy — similar to how human physicians and veterinarians use radioactive iodine to treat hyperthyroidism in humans and animals.

This treatment option may be valuable for reducing the disease's burden before starting anti-viral therapy. Or, it may serve as a rescue treatment for cats that suffer a relapse after a long course of anti-viral drugs. 🐾

*The Sylvia Fedoruk Canadian Centre for Nuclear Innovation is funding this research project.*

*Dorsa Mehrabanpour is a master's student in the WCVN's Department of Veterinary Biomedical Sciences at the University of Saskatchewan.*

*Veterinarians can contact Dr. Liz Snead (liz.snead@usask.ca) for more details about applying for FIP medication through Health Canada's Emergency Drug Release program of the Veterinary Drugs Directorate.*

Visit [cahfpets.ca](http://cahfpets.ca) to read the unabridged version of this story

## WCVN research fund unveils new pet projects

Thanks to a record number of grant applications, the Companion Animal Health Fund (CAHF) is investing more than \$152,000 in 10 pet health research projects for 2024-25.

These studies, which focus on a range of companion animal health issues, will be conducted by Western College of Veterinary Medicine (WCVN) researchers and their collaborators. For more details about the new projects, visit [cahfpets.ca](http://cahfpets.ca).

**Assessing the efficacy and safety of glucagon for treating severe hypoglycemia in cats**

*Drs. Elisabeth Snead and Jessica Lam, WCVN*

**Characterization of Wilms tumour 1 expression in normal and neoplastic tissue of cats and dogs**

*Dr. Melissa Meachem, WCVN*

**Use of cone-beam computed tomography scans instead of diagnostic computed tomography scans for radiation treatment planning of canine sinonasal tumours**

*Drs. Monique Mayer, Eriola Hida and Sally Sukut, WCVN; Dr. Michele Keyerleber, Tufts University; and Dr. Narinder Sidhu, B.C. Cancer Centre*

**Deciphering tumour heterogeneity: thorough necropsy, imaging and transcriptomics in naturally occurring cancers in dogs**

*Drs. Arata Matsuyama and Jasmine Yu Gu, WCVN; Dr. Dean Chamberlain, USask College of Medicine; and Dr. Michael Zabrodski, Prairie Diagnostic Services*

**Pharmacokinetics of intranasal or intramuscular atipamezole in dogs with and without xylazine**

*Drs. Jen Loewen, Vanessa Cowan and Al Chicoine, WCVN*

**Comparison of immune checkpoint molecules expression in lymphoma and reactive lymphocytic populations in cats and dogs**

*Drs. Ryan Dickinson, Alireza Rocky, Bruce Wobeser, Valerie MacDonald Dickinson, Nicole Fernandez and Melissa Meachem, WCVN; and Dr. Jennifer Davies, University of Calgary*

**Solensia versus placebo for the treatment of obstructive feline interstitial cystitis in male cats**

*Dr. Kevin Cosford, WCVN*

**Efficacy comparison of two durations of amoxicillin therapy for uncomplicated urinary tract infections in dogs**

*Drs. Al Chicoine and Joe Rubin, WCVN*

**Expression and function of ATP synthase inhibitory factor-1 in hemangiosarcomas**

*Drs. Gurpreet Aulakh, Behzad Toosi and Arata Matsuyama, WCVN*

**Cardiorespiratory effects of sedation with alfaxalone-midazolam-hydromorphone or dexmedetomidine-midazolam-hydromorphone prior to isoflurane anesthesia in healthy rabbits**

*Drs. Barbara Ambros, Shannon Beazley and Isabelle Duprez, WCVN*



UNIVERSITY OF  
SASKATCHEWAN

*Vet Topics* is the news publication for the Western College of Veterinary Medicine's Companion Animal Health Fund. Visit [cahfpets.ca](http://cahfpets.ca) for more information.

Managing editor: Myrna MacDonald

Comments? Contact [wcvn.communications@usask.ca](mailto:wcvn.communications@usask.ca)

*Vet Topics* design and layout: Priddy Design

*Vet Topics*, WCVN, U of S, 52 Campus Drive, Saskatoon, SK S7N 5B4

To report a change of address or to request a withdrawal from the mailing list, contact: [pet.health@usask.ca](mailto:pet.health@usask.ca).

# Banned poison still endangers pets' lives

By Tyler Schroeder

Despite a year-old ban on the use of strychnine to control rodents, pets and other animals remain at risk.



Dr. Vanessa Cowan, an assistant professor at the Western College of Veterinary Medicine (WCVM), says the number of reported dog poisonings has persisted over the last year.

Strychnine, a rodenticide that affects the nervous system of animals, was previously used across Canada to control rodent populations. In March 2021 Health Canada's Pest Management Regulatory Agency de-registered strychnine due to its harmful effects on animals accidentally poisoned. In March 2023, the Saskatchewan Ministry of Agriculture

banned the use of strychnine following a phase-out period of two years.

Cowan says recent cases of strychnine poisonings in dogs are very concerning.

"Within 15 to 20 minutes of ingestion, the animal will start seizing which is characterized by very stiff limbs or extensor rigidity. The extensor muscles will pull the legs straight and keep them stiff," says Cowan.

With limited treatment options for animals poisoned with strychnine, veterinary teams can only provide supportive care to try to control seizures. Cowan

says most animals die within a few hours of ingesting the poison.

Dogs have been the primary victims in Cowan's case data, but she noted horses, cattle, scavenging birds and other animals have also been poisoned.

Strychnine use can also lead to "secondary toxicity" where animals are poisoned after consuming the carcasses of strychnine victims. Additionally, rural and urban poisonings have occurred — further complicating efforts to pinpoint the source of the poison.

"In the cases that we've looked at, the owners of the animals weren't using strychnine on their farms. But because it's been used for a long time in controlling certain populations, someone may still be using it because they know it'll effectively take care of a problem," said Cowan.


To replace strychnine, the Saskatchewan Ministry of Agriculture approved the use of zinc phosphide to control rodent populations in March 2023. Zinc phosphide doesn't accumulate or persist in animal tissue, which makes it less likely to cause secondary poisonings. But there are still serious risks linked to zinc phosphide's use, says Cowan.

She hopes public awareness about the dangers of strychnine and other toxins will help decrease the number of poisonings. She recommends pet owners be cautious before allowing animals to roam in unfamiliar environments.

"It's an extremely distressing problem for dog owners and dogs. People need to know that strychnine poisonings are still occurring, and fatalities are common with something this toxic. If your animal is showing clinical signs such as seizing or extensor rigidity, seek immediate help from your veterinarian." 🐾

**Emergency poison information for animals:** contact your local veterinarian or call 1-855-764-7661 (Pet Poison Helpline, available throughout North America, incident fee applies). **Emergency poison information for people:** call 911 or call 1-844-764-7669 (toll-free).

Visit [cahpets.ca](http://cahpets.ca) to read the unabridged version of this story.



Dr. Nolan Chalifoux conducted the Addison's disease study when he was still a WCVM student.

Supplied

# Diagnostic clues for Addison's disease

By Cat Zens

Researchers at the University of Saskatchewan (USask) have identified unique characteristics of critically ill dogs suffering from Addison's disease — insights that may help veterinarians identify severe cases more quickly.

Addison's disease (canine hypoadrenocorticism) results from deficiencies in two adrenal gland hormones, cortisol and aldosterone. While the disease is manageable in most cases, severe instances can be fatal if left untreated. Affected dogs require lifelong steroid therapy to supplement hormone levels and manage the disease.

Published in the *Canadian Veterinary Journal* in July 2023, the study's findings are based on a review of 84 cases of Addison's disease in dogs treated at the Western College of Veterinary Medicine's (WCVM) Veterinary Medical Centre between 1998 and 2018.

In non-critical cases, dogs may experience mild clinical signs such as softer stools. Critically ill dogs can show signs such as vomiting, diarrhea, markedly low blood pressure and electrolyte changes — potentially leading to cardiac arrhythmias or other severe heart issues. They can also experience a hypoglycemic crisis, causing low blood sugar and potential seizures.

After reviewing medical records, WCVM scientists found that collapse and depression were prevalent signs among critically ill dogs — along with vomiting, diarrhea and shock. Researchers noted that many of these dogs in shock had normal lactate levels despite a high lactate being traditionally associated with shock.

"If you're healthy and doing well, your lactate would be low ... if you're in shock and you're really dehydrated, your lactate increases," says Dr. Nolan Chalifoux, the study's lead author. "But [in this study], the dogs' lactate rates were still normal."

Stress hormones — including cortisol — may play a role in blood lactate formation. Chalifoux suggests that many dogs with Addison's disease may not have high lactate rates because they don't get enough cortisol, which may prevent lactate rates from rising.

"I think the main takeaway for someone who is working in an emergency clinic or an ICU is that these dogs might not be acting the way a normal dog acts if they're in shock — they might not have that high rate or that high lactate level," says Chalifoux.

The study found that separation — such as owners going away on vacation

— was one of the most common precipitating stressors in affected dogs.

"A lot of people who have dogs with Addison's disease are told that if there is a potential stressful situation happening, they should increase the dose of steroids that these dogs are on to help control their disease," says Chalifoux, a 2019 graduate of the WCVM. He's now a board-certified critical care specialist at a specialty and emergency pet hospital in Philadelphia, Penn.

Chalifoux conducted the study in 2018 as a WCVM summer student with Dr. Elisabeth (Liz) Snead, a small animal internal medicine specialist at the college. The study's other co-authors include Dr. Lyndsay Kong, a 2014 WCVM graduate, WCVM veterinary pathologist Dr. Hilary Burgess, and Dr. Cindy Feng, an adjunct faculty member at USask School of Public Health.

Chalifoux hopes the study's findings help veterinarians understand that dogs with Addison's disease may present atypically.

"I hope that people will better recognize these dogs have an ambiguous disease process, and hopefully, we'll be able to save more dogs by recognizing [the disease] earlier." 🐾

Visit [cahfpets.ca](http://cahfpets.ca) to read the unabridged version of this story

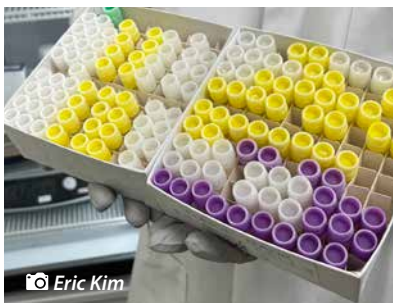
# WCVM's cancer tumour bank

By Eric Kim



Boh, owned by Mike Tremblay, underwent surgery and chemotherapy at the WCVM Veterinary Medical Centre.

📷 *Christina Weese*



📷 *Eric Kim*

**Cancer is a deadly disease, and our limited understanding of it is part of what makes it so dangerous.**

Last summer, I joined Dr. Arata Matsuyama, a specialist in veterinary medical oncology at the Western College of Veterinary Medicine (WCVM), and Dr. Behzad Toosi, an assistant professor and the WCVM's Allard Research Chair in Oncology, to learn more about cancer through a comparative oncology study.

Our work focused on building a "bank" of tumours sampled from dogs and cats to establish a knowledge base of various cancer types.

"Comparative oncology aims to help researchers better understand the biology of cancer. We hope to find new treatments

for both humans and animals by studying naturally occurring cancers in pets," says Matsuyama.

He adds that this area of research acts as "a stepping-stone" between humans and animals — two different yet surprisingly similar species in cancer formation.

The tumour bank program will benefit researchers by allowing easy access to a diverse bank of samples, representing a wide variety of cancer types.

"This will have important implications in identifying the genetic cause of different cancers and for finding the potential of improving the diagnosis and therapy of these cancers. That is the ultimate goal of our research."

The process begins by screening for patients that have tumours greater than three by three centimetres. We then ask the pets' owners for consent for tissue donation. Lastly, a tumour sample is collected post-surgery or through a biopsy.

Since the project's inception in fall 2022, WCVM oncologists have collected over 50 tumour samples across 20 different tumour types. In addition, cell lines from 25 tumour samples have been isolated and stored. The team continues to collect one or two samples every week.

The WCVM uses several methods to store the tissue samples and ensure viability for future analysis. These methods include freezing samples in liquid nitrogen as well as placing samples in formalin before encasing them in paraffin wax.

These storage methods allow access to various types of tissue samples from the same patient, while also being integral to the cell line (a collection of cells that originated from one cell) identification process. Identifying or authenticating a cell line ensures that it's correctly identified and not cross contaminated with other cells.

The WCVM research team's focus is on analyzing three tumour types: osteosarcoma, pulmonary carcinoma and soft tissue sarcoma in dogs. The team characterizes the tumour cells using two methods.

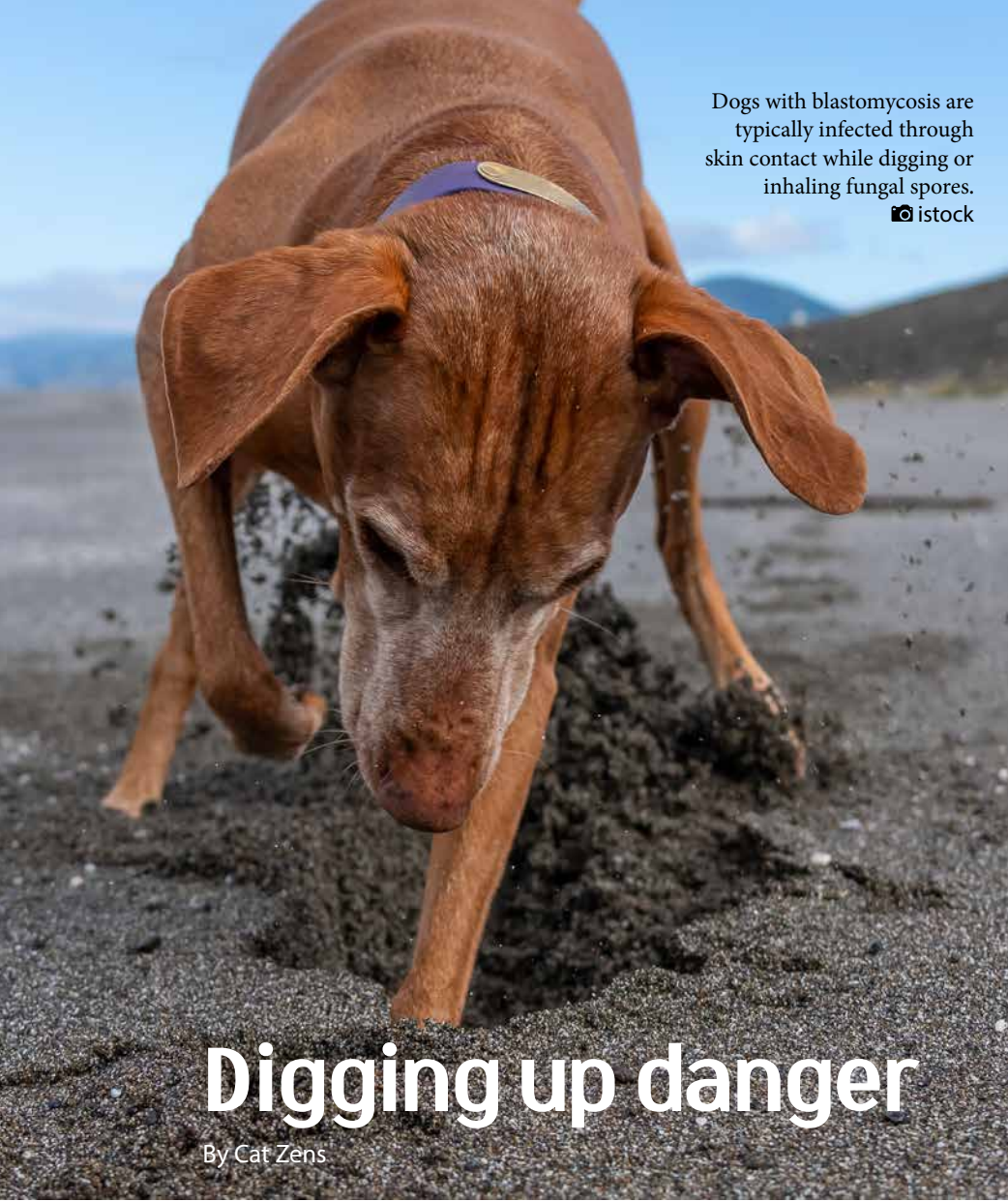Immunohistochemistry uses antibodies to confirm the protein expression profile of the samples and cancerous origin of the isolated cells. Soft agar colony formation assay (SACFA), predicts the degree of malignancy or aggressiveness of the tumour from which the cells were isolated.


The WCVM is now the second veterinary college in Canada to have a tumour bank, positioning the WCVM as a leader in Canadian veterinary oncology. This opens avenues for increased research funding and plays a significant role in advancing comparative oncology. 🐾

*The WCVM Companion Animal Health Fund (CAHF) provided funding for this project.*

*Eric Kim of Coquitlam, B.C., is a fourth-year veterinary student at the WCVM. His story is part of a series of articles written by WCVM summer research students.*

Visit [cahfpets.ca](http://cahfpets.ca) to read the unabridged version of this article.



Dogs with blastomycosis are typically infected through skin contact while digging or inhaling fungal spores. 

# Digging up danger

By Cat Zens

As dogs dig holes and sniff their surroundings during their daily walks, owners should be aware of a potentially fatal fungal disease that could infect their pets.

Blastomycosis is a disease caused by *Blastomyces dermatitidis*, a type of fungus that lives in moist soils throughout eastern North America. The fungus can be found on the Prairies — most commonly in southern Saskatchewan and Manitoba.

Dr. Mathieu Paulin is a small animal internal medicine resident and PhD student at the Western College of Veterinary Medicine (WCVM) who works with prairie-based blastomycosis cases in the college's Veterinary Medical Centre (VMC).

"People call me the magnet for fungal diseases," he quips.

He adds that *B. dermatitidis* is particularly active in dust-producing regions, especially during rainy seasons. Although blastomycosis is relatively uncommon on the Prairies, dog owners should be aware of the disease — especially in high-moisture areas.

Dogs with blastomycosis are typically infected through skin contact while digging or inhaling fungal spores. While the disease is most common in the lungs, it can affect almost any part of the dog's body, and can spread to multiple body parts if not treated quickly enough.

Paulin adds that blastomycosis transmission isn't likely between dogs or from dogs to humans. However, localized *Blastomyces* infections have occurred in health care workers who work with the fungal culture in the lab.

Because most dogs spend a lot of time outside surrounded by dust and soil, preventing them from infection is nearly impossible.

"You would have to forbid your dog to sniff outside, which is pretty hard to do," Paulin says. He adds that dog owners' best option is to act as soon as they first see signs of illness in their pet.

But the clinical signs of blastomycosis are challenging to identify. For example, coughing, heavy breathing, decreased appetite, fatigue and weight loss can all be indicators of this illness — as well as many other conditions. If a dog is showing any of these signs, Paulin recommends taking them to a veterinarian for an examination.

"All positive cases of blastomycosis should be treated," he says. "You need to treat [the dogs] as soon as possible."


Paulin says the VMC typically sees between five and 10 blastomycosis cases in canine patients every year. However, the number of infections is likely higher due to difficulty in diagnosis and the associated costs.

Diagnostic procedures alone can range from \$1,500 to \$5,000. Paulin explains that veterinarians usually make a definitive diagnosis based on the combined results from X-rays, blood tests, urine tests and sampling of the lesions.

Treatment typically involves antifungal medications, such as itraconazole — costing roughly \$200 per month — administered over two to three months. Surgery may also be necessary in some cases.

Antifungal medications stop the formation of a constituent (ergosterol) of fungal cell membranes (such as the skin surrounding the fungus) and causes the fungus to die.

According to Paulin, blastomycosis therapy has a success rate of 70 to 80 per cent, and most dogs respond positively to treatment. However, relapses are possible despite appropriate therapy.

"The earliest the dogs get treatment, the better chance they will have to survive," he says. 

*If you suspect that your dog has potential clinical signs of blastomycosis, contact your local veterinarian or call the VMC's Small Animal Clinic (306-966-7126).*

*Cat Zens of North Battleford, Sask., worked as a research communications intern at the WCVM in 2023.*

Visit [cahfpets.ca](http://cahfpets.ca) to read the unabridged version of this story.

# RESEARCH IN PRINT

A roundup of WCVM-related companion animal research articles that have been recently published in peer-reviewed journals.

Moreno D, Cosford K, Snead E, Carr A. "Assessment of hemostasis in hyperthyroid and euthyroid cats using two viscoelastic assays and platelet aggregometry." *Journal of Veterinary Internal Medicine*. Feb. 2024. DOI: 10.1111/jvim.17038.\*

Zvionow P, Reyes DM, Aburto E. "Obstructive cardiac myxosarcoma of the right ventricular outflow tract with pulmonary embolism and concurrent right atrial hemangiosarcoma in a dog." *The Canadian Veterinary Journal*. March 2024. 65(3): 234-240(7).

Curso-Almeida P, Subramaniam M., Gallagher A, Adolphe JA, Drew MD, Loewen ME, Weber LP. "Determining the effects of *Candida utilis*-fermented pea starch vs. unfermented pea starch, alone or in whole diets, on palatability and glycemic response in dogs and cats." *Journal of Animal Physiology and Animal Nutrition*. Feb. 2024. 1-16. <https://doi.org/10.1111/jpn.13940>.

Lyons C, McEwan K, Munn-Patterson M, Vuong S, Alcorn J, Chicoine A. "Pharmacokinetic of two oral doses of a 1:20 THC:CBD Cannabis herbal extract in cats." *Frontiers in Veterinary Science*. Feb. 2024. DOI: 10.3389/fvets.2024.1352495.

Bedos L, Sandmeyer L, Campbell J, Grahn BH. "Prevalence of pre-iridal monocellular and fibrovascular membranes in canine globes affected with congenital glaucoma associated with anterior segment dysgenesis, primary glaucoma associated with goniodysgenesis, and secondary glaucoma." *Frontiers in Veterinary Science*. Feb. 2024. DOI: 10.3389/fvets.2024.1289283.\*

Zadeh AS, Boston SE. "Avulsion of the lateral origin of the gastrocnemius muscle mimicking cranial cruciate ligament deficiency in a dog." *Vet Record Case Reports*. Dec. 2023. <https://doi.org/10.1002/vrc2.789>.

Focken AP, Woodsworth JM, Loewen JM. "Evaluation of the use of intranasal atipamezole to reverse the sedative effects of xylazine in dogs." *Journal of Veterinary Emergency and Critical Care*. Jan.-Feb. 2024. 34(1):57-62. doi: 10.1111/vec.13357.

Denenberg S, Machin K, Landsberg G. "Behaviour and cognition of the senior cat and its interaction with physical disease." *Canine and Feline Behavior, An Issue of Veterinary Clinics of North America: Small Animal Practice*. Nov. 2023. E-book. ISBN: 0443129983, 9780443129988.

Liversidge BD, Dodd SAS, Adolphe JL, Gomez DE, Blois SL, Verbrugghe A. "Extruded diet macronutrient digestibility: plant-based (vegan) vs. animal-based diets in client-owned healthy adult dogs and the impact of guardian compliance during in-home trials." *Frontiers in Animal Science*. Dec. 2023. DOI=10.3389/fanim.2023.1288165.

Paulin MV, Cross N, Gu J, Perkel M, Snead E. "Hypodipsic hypernatremia after long-standing polydipsia in a cat with suspect neonatal head trauma." *Canadian Veterinary Journal*. Nov. 2023. 64(11):1021-27. PMID: 37915774.

Mills EP, Liu C-C, Mironovich MA, Taylor CM, Meng L, Ugochi E, Scott EM, Leis ML, Carter RT, Pilar C-L, Lewin A. "Relationship between the bacterial ocular surface microbiota and outcomes for cats with feline herpesvirus type 1 ocular surface disease." *Veterinary Ophthalmology*. Oct. 2023; 00:1-12. doi:10.1111/vop.13157.

Kliwer M, Gu J, Paulin MV, Sukut S, Cosford K. "Computed tomographic and bronchoscopic diagnosis of *Oslerus osleri* infection in a dog." *Veterinary Radiology and Ultrasound*. Oct. 2023; 64: E83-E87. <https://doi.org/10.1111/vru.13301>.

Roberts C, Woodsworth J, Carlson K, Reeves T, Epp T. "Defining the term 'underserved': A scoping review towards a standardized description of inadequate access to veterinary services." *The Canadian Veterinary Journal*. Oct. 2023. 64(10):941-950. PMID: 37780475.

Desprez I, Crookes A, Di Girolamo M, Ambros B. "Subcutaneous administration of hydromorphone (0.2 mg/kg) provides antinociception in ferrets (*Mustela putorius furo*)." *American Journal of Veterinary Research*. Aug. 2023. 84(10):1-7. <https://doi.org/10.2460/ajvr.23.05.0099>.

Ericksen T, Mauldin N, Dickinson R, Mauldin G. "Single high-dose radiation therapy and liquid fiducial markers can be used in dogs with incompletely resected soft tissue sarcomas." *Journal of the American Veterinary Medical Association*. July 2023. 261(10):1-8. <https://doi.org/10.2460/javma.23.02.0119>.

Bokshowan E, Olver TD, Costa M, Weber LP. "Oligosaccharides and diet-related dilated cardiomyopathy in beagles." July 2023. *Frontiers in Veterinary Science*. DOI=10.3389/fvets.2023.1183301.\*

Allen KJH, Kwon O, Hutcheson MR, Grudzinski JJ, Cain SM, Cruz FA, Vinayakamoorthy RM, Sun YS, Fairley L, Prabakaran CB, Dickinson R, MacDonald-Dickinson V, Maruti U, Bednarz BP, Dadachova E. "Image-based dosimetry in dogs and cross-reactivity with human tissues of igf2r-targeting human antibody." July 2023. *Pharmaceuticals*. 16(7):979. <https://doi.org/10.3390/ph16070979>.

Osinchuk SC, Levitt S, Sandmeyer LS, Parker SE. "Evaluation of conjunctival graft procedures and factors that lead to graft complications in canine cases." *Veterinary Ophthalmology*. June 2023; 26:53-61. doi: 10.1111/vop.13008.

\*Funded by the WCVM Companion Animal Health Fund (CAHF).



# HONOUR THEIR LIVES WITH THE GIFT OF PET HEALTH

Pay tribute to the lives of your patients, clients and loved ones by making a donation to the Companion Animal Health Fund through its memorial program. Each time you give to the CAHF, we will send a letter to the client or loved one's family acknowledging your gift to the pet health fund.

"Town Centre Veterinary Hospital donates to the CAHF memorial program for each of our patients that passes away. It has been a very rewarding hospital policy — a win-win-win if you will — for the veterinary community, for our specific clients, and for our specific hospital."

**Dr. Pam Goble (WCVM '89)**  
CAHF donor

## Questions?


[wcvm.supportus@usask.ca](mailto:wcvm.supportus@usask.ca) | 306-966-7268



UNIVERSITY OF  
SASKATCHEWAN

**cahfpets.ca**

Dr. Pam Goble

 SUBMITTED

Check out *Vet Topics* online at [cahfpets.ca](http://cahfpets.ca)

PUBLICATIONS MAIL AGREEMENT NO. 40112792  
RETURN UNDELIVERABLE CANADIAN ADDRESSES TO:  
Research Office, WCVM  
University of Saskatchewan  
52 Campus Drive  
Saskatoon SK S7N 5B4  
[wcvm.research@usask.ca](mailto:wcvm.research@usask.ca)

Want more pet health news in your mailbox? Go to [cahfpets.ca](http://cahfpets.ca) and sign up to receive the *Vet Topics* e-newsletter online!